

PILONIDAL SINUS WOUNDS: SECONDARY INTENTION HEALING WITH A PLANT-BASED WOUND THERAPEUTIC

A. Lenz et al., Department of Surgery, Schwyz Cantonal Hospital, Switzerland
Wund Management 2015;9 (2) 48-53

OBJECTIVE/METHOD

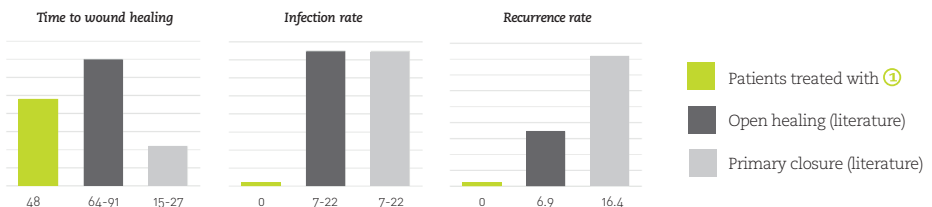
Pilonidal sinus is a chronic infection of the skin in the region of the buttock crease. It is thought that the condition results from a reaction to hairs embedded in the skin, commonly occurring in the cleft between the buttocks. The objective of this study

was to evaluate the effectiveness of ① in secondary intention healing of Pilonidal Sinus Wounds. 21 consecutive patients with a pilonidal sinus wound following a surgical excision were analysed retrospectively.

RESULTS

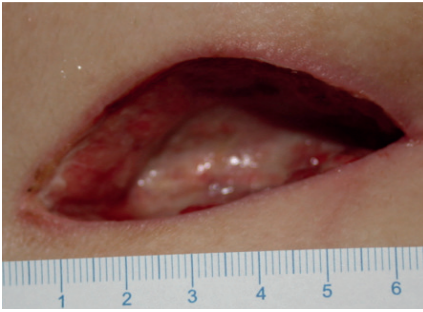
TEST PARAMETER	OPEN HEALING ①	OPEN HEALING (LITERATURE)	PRIMARY CLOSURE (LITERATURE)
Time to wound healing	48 days	64-91 days	15-27 days
Rate of surgical site infection	0%	7-22%	7-22%
Recurrence rate (follow-up period > 1 year)	0%	6.9%	16.4%
Time to return to work	14 days	17-28 days	11-15 days

Chart: Average time (days) to wound healing, rate of infection (%) and recurrence rate (%) - study result compared to literature

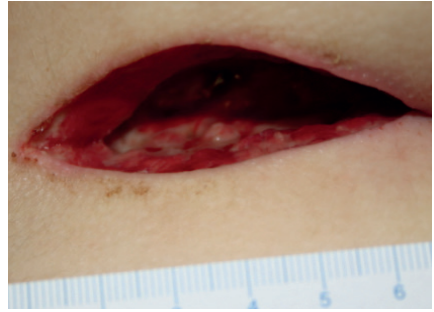


CASE REPORT

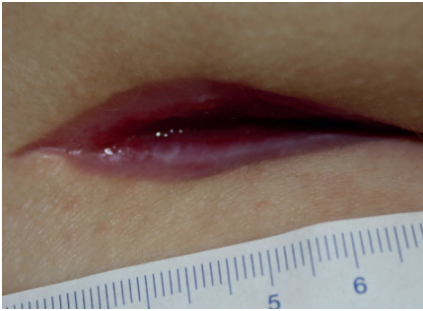20-year-old female patient with a 4cm deep and 19 cm² large pilonidal sinus wound



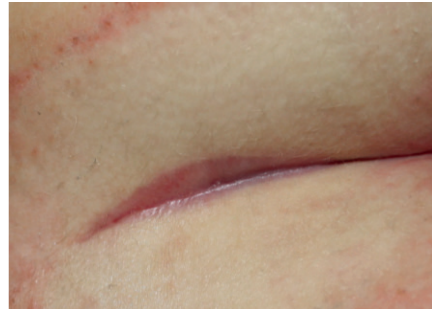DAY 3 Healthy wound with some fibrin coating



DAY 14 Clean wound, visible induction of granulation tissue growth



DAY 28 Rapid filling-up of the wound with granulation tissue



DAY 57 Complete wound closure with a good cosmetic result

TESTIMONIAL



Anne Lenz, MD
Schwyz Cantonal Hospital

“The average time to wound healing for the 21 patients treated with ④ was 48 days, which appears faster than healing rates found in literature for secondary healing. This is a clear indication for the impressive granulation effect resulting from the application of ④, which led to a progressive filling up even of large skin defects.”

“Taking all observed factors together, the application of ④ clearly has the potential to offer clinical and economic benefits, making the secondary healing of pilonidal sinus wounds more effective.”